

# The Nexus of Communication and Diagnosis: A case-based interdisciplinary approach



Loma Linda University  
School of Dentistry

*October 21, 2018*

*Presenters:*

**Adrian Cotton, MD, Heidi Christensen, DDS, MS  
Eun-Hwi Cho, DDS, Jody Gonzalez, PharmD, MSG  
Alireza Hayatshahi, PharmD, BCPS, Amy Hayton, MD,  
Jessa Koch, PharmD, BCPS, Juan Najarro, MD,  
Erin Richards, DDS, Cambria Speyer, OT**

**Today's lunch sponsored by:  
School of Pharmacy**

*Guest Wi-Fi  
Username: lluguest  
Password: Discovery@1492*

*School of Dentistry Continuing Education  
Loma Linda, California 92350  
Tel: (909) 558-4685  
Fax: (909) 558-0835  
[www.llu.edu/llu/dentistry](http://www.llu.edu/llu/dentistry)*

## **Mission Statement**

Our mission in continuing dental education is to enhance the dentist's ability to care for patients. It is our responsibility as the accredited sponsor of continuing dental education activities to assure that the activity is designed for this purpose.

## **Disclaimer Statement**

Continuing education programs offered by Loma Linda University School of Dentistry are intended to be for review and/or introduction purposes only. Additional training may be necessary to become fully proficient in any area or technique within dentistry.

This event will be photographed. The term "photograph," as used, shall mean motion picture or still photography in any format or any medium including video tape or disc, digital recording, or any other means of recording and reproducing images. Loma Linda University School of Dentistry (LLUSD) has the right to use and reproduce said photography.

## **Disclosure Statement**

Dr. Adrian Cotton, has no relationships to disclose relative to this continuing dental education program.

Dr. Heidi Christensen, has no relationships to disclose relative to this continuing dental education program.

Dr. Eun-Hwi Cho, has no relationships to disclose relative to this continuing dental education program.

Dr. Jody Gonzalez, has no relationships to disclose relative to this continuing dental education program.

Dr. Alireza Hayatshahi, has no relationships to disclose relative to this continuing dental education program.

Dr. Amy Hayton, has no relationships to disclose relative to this continuing dental education program.

Dr. Jessa Koch, has no relationships to disclose relative to this continuing dental education program.

Dr. Juan Najarro, has no relationships to disclose relative to this continuing dental education program.

Dr. Erin Richards, has no relationships to disclose relative to this continuing dental education program.

Dr. Cambria Speyer, has no relationships to disclose relative to this continuing dental education program.

**The Nexus of Communication and Diagnosis: A case-based interdisciplinary approach**  
**Sunday, October 21, 2018**  
**Loma Linda University School of Dentistry**

**Synopsis**

Although we all work on the same patients, those of us in healthcare communicate differently and often have very different concerns regarding the same patient diagnosis. Due to these siloed perspectives, the Interprofessional Education Collaborative (IPEC), a national institute founded in 2009, has joined together twenty different national healthcare associations “to help prepare the future health professionals for enhanced team-based care of patients and improved population health outcomes.” Utilizing other healthcare professional colleagues’ expertise would minimize the risk of practice and prescription errors significantly. An interprofessional patient-centered care model will provide the safest and most efficient treatment. By understanding each other's perspectives better, we can communicate and collaborate more effectively. This is a case-based opportunity to learn and apply these very principles.

**Objectives**

By the end of the conference, attendees will be able to:

- Describe how interprofessional communication, assessment and collaboration changes patient care.
- Discuss why multidisciplinary communication, assessment and collaboration is necessary for efficient patient care.
- Review how to apply this new concept of interprofessional collaboration in a simulated clinical setting.
- Discuss how to minimize practice related risks to our patients by utilizing other health care professional expert opinion.

**8:30 am      Registration**

**9:00 am      Welcome, Introductions and Overview**  
Erin Richards, DDS – Program facilitator  
Eun-Hwi Cho, DDS

Objectives

- Educate audience in regards to the history and necessity of interprofessional education
- Gauge the past and current interprofessional experience and attitudes of the audience.

**9:15 am      Case Set One**

- Case one – 50 year old male with hypertension, HIV and recent heart attack
- Case two – 75 year old female with diabetes, previous breast cancer and history of stroke
- Case three – 58 year old male with previous narcotics addiction and COPD
- Case four – 62 year old female with end stage renal disease and epilepsy

Presenters

Heidi Christensen, DDS  
Alireza Hayatshahi, PharmD, BCPS  
Eun-Hwi Cho, DDS  
Adrian Cotton, MD

Objectives

- Describe and discuss *communication* between dentists, pharmacists and physicians regarding health conditions pertaining to kidney disease, cancer, cardiology and hematology.
- Describe and discuss *bioethical discrepancies* between dentists, pharmacists and physicians regarding health conditions pertaining to kidney disease, cancer, cardiology and hematology.
- Describe and discuss *roles and responsibilities* of dentists, pharmacists and physicians regarding health conditions pertaining to kidney disease, cancer, cardiology and hematology.
- Describe and discuss *teamwork and collaboration* between dentists, pharmacists and physicians regarding health conditions pertaining to kidney disease, cancer, cardiology and hematology.
- In-class simulated case application of interprofessional communication, bioethics, roles and collaboration.

**10:30 am      Break**

**10:45 am      Case set one continued**

**12:00 noon    Lunch break**

**1:00 pm        Case Set Two**

- Case one – 65 year old male with schizophrenia, tardive dyskinesia and lack of social support
- Case two – 82 year old female with history of stroke, depression and an arm injury
- Case three – 23 year old male with bipolar disorder, insomnia and drug use

Presenters

Jody Gonzalez, PharmD  
Amy Hayton, MD  
Jessa Koch, PharmD  
Juan Najarro, MD  
Cambria Speyer, OT

Objectives

- Describe and discuss *communication* between dentists, pharmacists, physicians and occupational therapists regarding health conditions pertaining to neurology, psychology, stroke and arm injury.

- Describe and discuss *bioethical discrepancies* between dentists, pharmacists, physicians and occupational therapists regarding health conditions pertaining to neurology, psychology, stroke and arm injury.
- Describe and discuss *roles and responsibilities* of dentists, pharmacists, physicians and occupational therapists regarding health conditions pertaining to neurology, psychology, stroke and arm injury.
- Describe and discuss *teamwork and collaboration* between dentists, pharmacists, physicians and occupational therapists regarding health conditions pertaining to neurology, psychology, stroke and arm injury.
- In-class simulated case application of interprofessional communication, bioethics, roles and collaboration.

**2:15 pm Break**

**2:30 pm Case set two continued**

**4:00 pm Open discussion regarding cases pertaining to the following:**

- Discuss participants' clinical experience with interprofessional communication, bioethics, roles and collaboration regarding case set one and case set two health conditions.
- Describe other healthcare related clinical applications of interprofessional communication, bioethics, roles and collaboration.

**By 4:30 pm Adjourn**

### References

1. American Dental Association. 2018. *American Dental Association*. [ONLINE] Available at: <https://www.ada.org/en>. [Accessed 1 June 2018].
2. American Medical Association. 2018. *American Medical Association*. [ONLINE] Available at: <https://www.ama-assn.org/>. [Accessed 1 June 2018].
3. American Pharmacists Association. 2018. *American Pharmacists Association*. [ONLINE] Available at: <https://www.pharmacist.com/>. [Accessed 1 June 2018].
4. Interprofessional Education Collaborative. 2018. *Interprofessional Education Collaborative*. [ONLINE] Available at: <https://www.ipecollaborative.org/>. [Accessed 1 June 2018].
5. National Institutes of Health. 2018. *National Institutes of Health*. [ONLINE] Available at: <https://www.nih.gov/>. [Accessed 1 June 2018].
6. World Health Organization. 2018. *World Health Organization*. [ONLINE] Available at: <https://www.who.int/>. [Accessed 1 June 2018].

# CASE SET #1



Loma Linda University  
School of Dentistry

---

---

---

---

---

---

---

---

## Case Set #1 - Objectives

- » Describe and discuss *communication* between dentists, pharmacists and physicians regarding health conditions pertaining to kidney disease, cancer, cardiology and hematology.
- » Describe and discuss *bioethical discrepancies* between dentists, pharmacists and physicians regarding health conditions pertaining to kidney disease, cancer, cardiology and hematology.
- » Describe and discuss *roles and responsibilities* of dentists, pharmacists and physicians regarding health conditions pertaining to kidney disease, cancer, cardiology and hematology.
- » Describe and discuss *teamwork and collaboration* between dentists, pharmacists and physicians regarding health conditions pertaining to kidney disease, cancer, cardiology and hematology.
- » In-class simulated case application of interprofessional communication, bioethics, roles and collaboration.



Loma Linda University  
School of Dentistry

---

---

---

---

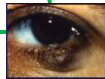
---

---

---

---

## Case #1



**Chief Complaint:**  
Patient is in severe pain. #14 has an acute apical abscess with a vertical root fracture. Pt is concerned it affecting his eye/sinus area. Surgical extraction of #14 is warranted.

**Medications:**  
Aspirin 81 mg 1x/day  
Coumadin 5mg 1x/day  
Lipitor 40mg 1x/day  
Metoprolol XL 25 mg 2x/day  
DRV/c+ (FTC/TAF)  
DRV: 800 mg po once daily  
FTC/TAF: 200mg/25mg

**Health History Profile:**  
50 year old male  
Hypertension  
Recent Heart Attack  
Morphine Allergy  
Penicillin Allergy  
Prosthetic Heart Valve  
Previous Infective Endocarditis  
Smoker



Loma Linda University  
School of Dentistry

---

---

---

---

---

---

---

---

**Hypertension**

**S:** Pt says he has had hypertension for about 6 years now. He sees his physician every 6 months. He takes Metoprolol for this condition. His BP at the doctor's office is usually about 120-130/ 80. Pt says his physician is pleased with how stable his blood pressure is. Pt says he has had a heart attack but he walks every day.

**O:** BP: 128/78, HR: 70 bpm



Loma Linda University  
School of Dentistry

---

---

---

---

---

---

---

---

**Recent Heart Attack**

**S:** Pt says he had a heart attack. He was hospitalized for this. He sees his cardiologist every week right now. He takes high cholesterol medication and aspirin now. He does not experience chest pain. He walks 2 miles every day now.

**O:** BP: 128/78, HR: 70 bpm



Loma Linda University  
School of Dentistry

---

---

---

---

---

---

---

---

**Heart Valve**

**S:** Pt says he got an infection of the inside of the heart about 4 years ago. After that he received a new heart valve. He has not had an infection of the heart since and sees his cardiologist every week at the moment. His physician says he needs antibiotics before dental treatment.

**O:** None



Loma Linda University  
School of Dentistry

---

---

---

---

---

---

---

---



### Case #2

**Chief Complaint:**  
Patient is in pain. #3 has necrotic pulp with Class II mobility. Simple extraction of #3 is warranted.

**Medications:**  
Boniva IV 6mg/month  
Plavix 75 mg 1x/day  
Metformin 1,000 mg 2x/day

**Health History Profile:**  
75 year old female  
Past Tonsillar Cancer  
Type II Diabetic  
Stroke  
Overweight  
Sleep Apnea  
Hip replacement

---

---

---

---

---

---

---

---

---

---

### Diabetes

**S:** Pt says she has had Type II Diabetes for about 30 years now. She sees her physician every year or so. She takes Metformin for her condition. She takes her blood sugar 1-2x/week. It is usually about 240 mg/dl. She is not sure if that is good or bad and doesn't remember. She has had a hard time controlling her diabetes.

**O:** None

---

---

---

---

---

---

---

---

---

---

### Tonsillar Cancer

**S:** Pt says she had tonsillar cancer about 20 years ago. Her tonsillar tissue was removed surgically. There was no metastasis but she had radiation treatment with no significant side effects except for dry mouth. Since the radiation treatment, she has noticed her mouth is dry and the skin on her neck area is dry.

**O:** Pt's mouth appears dry

---

---

---

---

---

---

---

---

---

---

**Stroke**

**S:** Pt says she had a stroke in the past. She said she was doing yard work at the time and suddenly felt very dizzy and passed out. She is taking Plavix every day. Pt reports her physician says she had a stroke as a complication of her diabetes. No lingering complications due to the stroke. Pt is not nervous about dental treatment.

**O:** BP: 110/75



Loma Linda University  
School of Dentistry

---

---

---

---

---

---

---

---

**Sleep Apnea**

**S:** Pt says she is not aware of any sleep problems. Her husband says she snores at night.

**O:** Scalloped tongue, uvula elongated, generalized moderate attrition, Class II skeletal jaw relationship, short neck, floppy soft palate are all noted clinically



Loma Linda University  
School of Dentistry

---

---

---

---

---

---

---

---

**Hip Replacement**

**S:** Pt says she had a hip replacement about one year ago with no complications. Pt says her Orthopedic physician wants her to take antibiotics before dental treatment.

**O:** None



Loma Linda University  
School of Dentistry

---

---

---

---

---

---

---

---

### Case #3

**Chief Complaint:**  
Patient had 4 impacted wisdom teeth surgically removed 3 days ago. Oral Surgeon gave him Percocet for 3 days. Pt is calling for a refill because he is still in pain and out of the country.

**Health History Profile:**

58 year old male  
Ex-smoker  
COPD  
Current Outpatient Rehab for Narcotics Addiction  
Anxiety

**Medications:**  
Aspirin 325 mg 1x/day  
Albuterol 2 puffs up to 6x/day  
Spiriva 2 puffs/day  
Dexamethasone 10 mg right away, 5mg q12 hrs  
Percocet (325/5) 1 Tab q4-6 hrs prn



Loma Linda University  
School of Dentistry

---

---

---

---

---

---

---

---

---

---

### Chronic Obstructive Pulmonary Disease

**S:** Pt says he has had COPD for about 8 years now. He sees his physician every 6 months. He takes Spiriva and Albuterol for this condition, daily. His doctor says he has moderate COPD. He has been on medication for the last 2-3 years. He uses 1-2 pillows at night and he uses oxygen at night. He says he can walk a city block without breathing problems on "a good day." On a bad day, he needs to stop and catch his breath. He says lying down in a dental chair too far could cause him to have problems breathing if it is for too long and too far back.

**O:** Resp: 20



Loma Linda University  
School of Dentistry

---

---

---

---

---

---

---

---

---

---

### Narcotics Addiction

**S:** Pt says he is currently in rehabilitation for narcotics addiction, specifically "Oxycontin." He has been as addict for about 20 years and is just now getting help. He says he is in the early stages. No medications have been prescribed to him so far. He is really glad he is getting help. Pt says he has not taken any pain medication since he started rehabilitation.

**O:** None



Loma Linda University  
School of Dentistry

---

---

---

---

---

---

---

---

---

---

**Anxiety**

**S:** Pt says he has never been diagnosed with anxiety but he is deathly afraid of the dentist. He says he loses sleep the night before. He has had “a pill” beforehand that calmed him down. He really liked that. He has never tried “laughing gas,” and doesn’t want to. Pt says he will need something especially for when we take out his teeth.

**O:** Pt appears anxious in the dental chair, BP: 130/85




---

---

---

---

---

---

---

---

**Case #4**

**Chief Complaint:**  
Patient had five non-restorable teeth surgically extracted after not having been to the dentist in years. She is in need of post-op pain and infection control.

**Medications:**  
Phenytoin 200mg tid 1x/day  
Atenolol 50 mg 1x/day  
Simvastatin 20 mg/day  
Vitamin D3 800 units/day

**Health History Profile:**  
62 year old female  
End Stage (4) Renal Disease  
Epilepsy  
Secondary  
Hyperparathyroidism




---

---

---

---

---

---

---

---

**Chronic Kidney Disease (CKD)**

**S:** Pt has Stage 4 Chronic Kidney Disease (CKD). She has had problems with her kidneys for years due to recurrent pyelonephritis. She sees her nephrologist every 3 months for blood work. Her last results were as follows: Serum Creatinine= 5.0 mg/dL (HIGH), GFR=25 mL/min (LOW), blood urea nitrogen (BUN)=60mg/dl (HIGH), Hematocrit=34% (LOW) and Hemoglobin=11 g/dL (LOW). She sees her physician every 3 months. Patient says she has no significant problems with bleeding/bruising or healing.

**O:** No bruising noted on patient’s skin




---

---

---

---

---

---

---

---

**Epilepsy**

**S:** Pt says she has had epilepsy for over 20 years. She takes Phenytoin for this condition and sees her regular physician every 6 months. Her last seizure was over 5 years ago. She rarely gets them anymore but she knows the trigger is high stress. She sees "stars" before a seizure. The seizure usually lasts about 2 minutes. Her arms flail or she is stiff and "zoned out." The dentist does make her nervous.

**O:** Pt does appear a little anxious in dental chair



Loma Linda University  
School of Dentistry

---

---

---

---

---

---

---

---

**Secondary Hyperparathyroidism**

**S:** Pt says she has had this condition for only about a year. She gets her calcium levels checked every 3 months. Her last reading was "normal," she says. She says this condition does not significantly affect her life. Pt takes Vitamin D3 for this condition.

**O:** No reported bony abnormalities noted on radiographs



Loma Linda University  
School of Dentistry

---

---

---

---

---

---

---

---

**CASE SET #2**



Loma Linda University  
School of Dentistry

---

---

---

---

---

---

---

---

### Case Set #2 - Objectives

- » Describe and discuss *communication* between dentists, pharmacists, physicians and occupational therapists regarding health conditions pertaining to neurology, psychology, stroke and arm injury.
- » Describe and discuss *bioethical discrepancies* between dentists, pharmacists, physicians and occupational therapists regarding health conditions pertaining to neurology, psychology, stroke and arm injury.
- » Describe and discuss *roles and responsibilities* of dentists, pharmacists, physicians and occupational therapists regarding health conditions pertaining to neurology, psychology, stroke and arm injury.
- » Describe and discuss *teamwork and collaboration* between dentists, pharmacists, physicians and occupational therapists regarding health conditions pertaining to neurology, psychology, stroke and arm injury.
- » In-class simulated case application of interprofessional communication, bioethics, roles and collaboration.



Loma Linda University  
School of Dentistry

---

---

---

---

---

---

---

---

---

---

### Case #1

<p><b>Chief Complaint:</b> Oral Hygiene and maintenance in a long term care facility</p>	<p><b>Health History Profile:</b></p> <p>65 year old male Schizophrenia Diabetes Hyperlipidemia Hypertension Obesity Wheelchair bound</p>
<p><b>Medications:</b></p> <p>Risperidone 2mg AM, 4mg PM Hydrochlorothiazide 25 mg/day Lisinopril 20 mg 2x/day Metformin 1,000 2x/day Lantus 45 units 2x/day Novalog (sliding scale) Atorvastatin 80 mg/day Stool softener</p>	



Loma Linda University  
School of Dentistry

---

---

---

---

---

---

---

---

---

---

### Schizophrenia

**S:** Diagnosed 40 yrs ago, in a long term care (LTC) facility now, hearing voices from time to time, voices are not threatening but interrupt him and distract him, tardive dyskinesia due to medication (sticking out tongue, teeth clenching, dry mouth), wheel chair, gynecomastia, stable on meds from lab tests results, pt gets check-ups every 3 months. It says that patient is moderately controlled on his chart. Chart says patient has a hard time understanding directions sometimes and doesn't like to communicate when stressed. Patient can get stressed out when he doesn't understand what is going on around him. There is a caregiver that has been assigned to this patient. She is present and seems to know his situation well.

**O:** Pt seems calm in dental chair, poor oral hygiene, pt has difficulty understanding nuances of dental care instructions



Loma Linda University  
School of Dentistry

---

---

---

---

---

---

---

---

---

---

**Diabetes**

**S:** Pt was diagnosed with Diabetes Type II about 20 years ago. He takes oral medication and Insulin every day to assist with control of his diabetes. Pt is obese, wheelchair bound with no significant complaint of lack of feeling in any extremities or difficulty with vision. Pt's blood sugar is taken once a day, in the morning. It is usually about 80 mg/dl. His A1C is tested every 3 months. His last A1C reading was 6.5%. His A1C was much higher before he came to the Long Term Care facility (LTC). He reports episodes of hypoglycemia especially when he is stressed out. He has such episodes a couple times a week. Pt is nervous about seeing a dentist. He has bad memories as a child with dentists. Pt reports no significant issues with healing.

**O:** Moderate periodontal disease noted



Loma Linda University  
School of Dentistry

---

---

---

---

---

---

---

---

---

---

**Hypertension**

**S:** Pt has had hypertension for about 20 years. He takes oral medication for this condition every day. Pt has his blood pressure checked every day. It is usually low, about 110/70. He gets his blood pressure checked with physician every 3 months. It is usually good at the physician's office.

**O:** BP=115/75



Loma Linda University  
School of Dentistry

---

---

---

---

---

---

---

---

---

---

**Case #2**

**Chief Complaint:**  
Oral Hygiene, needs an abscessed tooth extracted, pain

**Medications:**  
Insulin (bolus) 20 units/day  
Metformin 500 mg 2x/day  
Plavix 75 mg/day  
Aspirin 81 mg/day  
Lisinopril 20mg/day  
Metoprolol 25 mg bid  
Atorvastatin 80 mg/day

**Health History Profile:**  
82 year old female  
Cardiovascular Atherosclerosis  
Hypertension  
Diabetes  
History of Stroke  
Chronic Kidney Disease  
Recent right arm injury  
Depression



Loma Linda University  
School of Dentistry

---

---

---

---

---

---

---

---

---

---

History of Stroke

S: Pt had a stroke (R CVA) about 30 days ago due to previously uncontrolled hypertension. She was taken to the hospital and treated there. She sees her internist every 3-6 months. She has left-sided weakness on most of her left side including her left leg and left arm. She says she does bruise easily. She takes blood thinners (two anti-platelets) and sees her physician every 3 months. She says she just uses her right side, her left side is "useless." When asked if she can move it, she can move it some but it takes a little bit for her to do so. Pt says she is not stressed out about dental treatment.

O: Noticeable bruises and ecchymosis noted on hands and arms. You notice patient does not even raise left arm or move left side extremities with normal function and conversation. BP=138/70, HR=70.



Loma Linda University School of Dentistry

Horizontal lines for notes

Right Arm Injury

S: About two weeks ago patient injured her right arm, tripped over a rug at home and used her right arm to brace her fall since she is not using her left side. She says she just uses her right side, her left side is "useless." Pt broke her ulna in two places. She has surgery 1 week ago and it now in a cast with very limited mobility and range of motion. Pt has moderate vision impairment and can't drive. Elderly husband is 89 years old, hard of hearing and walks with a cane. He can still drive and can take care of himself for the most part. He is very adamant that he wants to help his wife in any way that he can. She says her husband can help with preparing food and helping her dress, etc. She says she, herself, can't do a lot of self-care, especially now.



Loma Linda University School of Dentistry

Horizontal lines for notes

Right Arm Injury continued

S (continued): She can't take care of her teeth now because she can't really reach them with her right arm. When asked if she can move her left arm she says yes but it takes a while for the left arm to move. Husband says she will often not even put her left arm through the shirt she is wearing for the day. He says she seems to "see her left side is she is told to look" but just doesn't use it or seem to care that it is not being used. Pt has recently been only eating the food on the right side of her plate.

O: You notice patient does not even raise left arm or move left side extremities with normal function and conversation. Pt's right arm is in a cast and sling.



Loma Linda University School of Dentistry

Horizontal lines for notes



**Hypertension**

**S:** Pt says that she has had hypertension for about 50 years now. She sees her internist every 3-6 months and has her blood pressure checked. It is usually "normal." She also checks her blood pressure with her home electronic system a few times a week in the morning. It is usually "normal" then, too. She has had a stroke 1 month ago but has never had a heart attack and does not have any chest pain. She can walk a block or flight of stairs without stopping to catch her breath. She is not nervous about dental treatment.

**O:** BP=138/70, HR=70



Loma Linda University  
School of Dentistry

---

---

---

---

---

---

---

---

---

---

**Diabetes**

**S:** Patient has had Type II diabetes for about 40 years. Pt is taking Insulin and Metformin for this condition. She sees her internist every 3-6 months for bloodwork. Pt take her blood sugar every morning before eating. It is usually about 145 mg/dl. Her last A1C was 8.5%. She does not report any problems with hypoglycemia or "low sugar" attacks but she does have delayed healing sometimes. Pt says she is not stressed out about dental treatment.

**O:** None



Loma Linda University  
School of Dentistry

---

---

---

---

---

---

---

---

---

---

**Chronic Kidney Disease**

**S:** Pt has Stage 3 Chronic Kidney Disease (CKD), diagnosed about 20 years ago. She has had problems with her kidneys due to diabetes and hypertension. She sees her internist every 3-6 months for blood work. Her last results were as follows: Serum Creatinine= 1.7 mg/dL (HIGH), GFR=35 mL/min (LOW), blood urea nitrogen (BUN)=10mg/dl (WNL), Hematocrit=39% (WNL) and Hemoglobin=12 g/dL (LOW). She says she does bruise easily. Pt has delayed healing.

**O:** Noticeable bruises and ecchymosis noted on hands and arms



Loma Linda University  
School of Dentistry

---

---

---

---

---

---

---

---

---

---

### Depression

**S:** Pt has Stage 3 Chronic Kidney Disease (CKD), diagnosed about 20 years ago. She has had problems with her kidneys due to diabetes and hypertension. She sees her internist every 3-6 months for blood work. Her last results were as follows: Serum Creatinine= 1.7 mg/dL (HIGH), GFR=35 mL/min (LOW), blood urea nitrogen (BUN)=10mg/dl (WNL), Hematocrit=39% (WNL) and Hemoglobin=12 g/dL (LOW). She says she does bruise easily. Pt has delayed healing.

**O:** Noticeable bruises and ecchymosis noted on hands and arms



Loma Linda University  
School of Dentistry

---

---

---

---

---

---

---

---

### Case #3

**Chief Complaint:**  
Needs multiple infected teeth extracted, no pain, want a maxillary anterior gold "grill"

**Health History Profile:**  
23 year old male  
Bipolar Disorder  
Cannabis Use  
Methamphetamine Use

**Medications:**  
None



Loma Linda University  
School of Dentistry

---

---

---

---

---

---

---

---

### Bipolar Disorder

**S:** Pt says he has had this "bipolar diagnosis" for about 2-3 years. He has refused medication, saying he "treats" himself with "weed." He only took medication in the hospital when he was first diagnosed. He has been hospitalized for this condition two times. Once when he was diagnosed and one more time about 1 year ago. He does not see a physician or psychiatrist on a regular basis. He recently moved out of his parent's house and now is living with a friend because he just decided to start his own corporation. He reports poor sleep, no more "really sad" episodes but he says he is pretty sure his friend's mom is trying to foil his business plans. He also says that YouTube sends him advice on how to make his business better. These messages are subliminal and not everyone can hear them. Pt says he is a little nervous about dental treatment.

**O:** Talking fast, HR=110, BP=150/90



Loma Linda University  
School of Dentistry

---

---

---

---

---

---

---

---

### Meth Use

**S:** Pt says he doesn't do drugs but says he has used methamphetamine at parties. He says it gives him a tremendous amount of energy and clarity. He feels like he gets his best and strongest ideas when he is on this. He also gets a lot of work done for his business. Meth has helped him be less sad. Pt says his mouth feels a little dry on a regular basis. Pt says he does not know if he grinds his teeth.

**O:** Pt has limited salivary flow, BP=150/90, HR=110, pt is talking fast, patient has 12 teeth that are decayed almost to the gum line and need to be extracted. No significant attrition noted.



Loma Linda University  
School of Dentistry

---

---

---

---

---

---

---

---

---

---

### Cannabis Use

**S:** Pt says he uses "weed" every day, 3-4x/day. He says this his main treatment for his bipolar. It has helped with his anxiety, fast heart rate, with sleep and his back pain. When asked about his back pain, patient says he has never had an injury, it is just from getting a little bit older. Pt says his mouth is a little dry on a regular basis. Pt says he does not know if he grinds his teeth.

**O:** Pt has limited salivary flow, HR=110, no significant attrition noted



Loma Linda University  
School of Dentistry

---

---

---

---

---

---

---

---

---

---

### References

- » American Dental Association. 2018. *American Dental Association*. [ONLINE] Available at: <https://www.ada.org/en>. [Accessed 1 June 2018].
- » American Medical Association. 2018. *American Medical Association*. [ONLINE] Available at: <https://www.ama-assn.org/>. [Accessed 1 June 2018].
- » American Pharmacists Association. 2018. *American Pharmacists Association*. [ONLINE] Available at: <https://www.pharmacists.com/>. [Accessed 1 June 2018].
- » Interprofessional Education Collaborative. 2018. *Interprofessional Education Collaborative*. [ONLINE] Available at: <https://www.ipeducollaborative.org/>. [Accessed 1 June 2018].
- » National Institutes of Health. 2018. *National Institutes of Health*. [ONLINE] Available at: <https://www.nih.gov/>. [Accessed 1 June 2018].
- » World Health Organization. 2018. *World Health Organization*. [ONLINE] Available at: <https://www.who.int/>. [Accessed 1 June 2018].



Loma Linda University  
School of Dentistry

---

---

---

---

---

---

---

---

---

---













